

**Clinical Evaluation of VP Function:
Instrumental Assessment**
腭咽闭合功能的临床器械诊断

University of Illinois at Urbana-Champaign
Department of Speech and Hearing Science
伊利诺伊大学 语音病理和听力学系
David P. Kuehn Ph. D.
Tian, Wei D. D. S.


Major Diagnostic Methods
主要器械诊断方法

- Endoscopy / Videonasendoscopy 内窥镜
- Radiography / Videofluoroscopy
放射影像学 / X线动态录像
- Nasometry 鼻音计

Other Procedures (Mainly Research)
其他诊断方法 (主要用于研究)

- Pressure Flow/Aerodynamics 压力-气流/空气动力学法
- Accelerometry 振动测量法
- Phototransduction 测光法
- Ultrasound 超声波
- Acoustic Analysis 声学分析
- Strain Gauge 张力计
- MRI 核磁共振
- Force 力学法
- EMG 肌电图

Videonasendoscopy 内窥镜

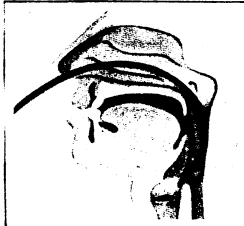

Components 组件:

1. Viewing lens 视镜
2. Fiberoptic insertion tube 光导纤维
3. Light source 光源
4. Eyepiece attached to a camera 连接至照像机

(Original figure from Peterson-Falzone et al.)

Videonasendoscopy 内窥镜



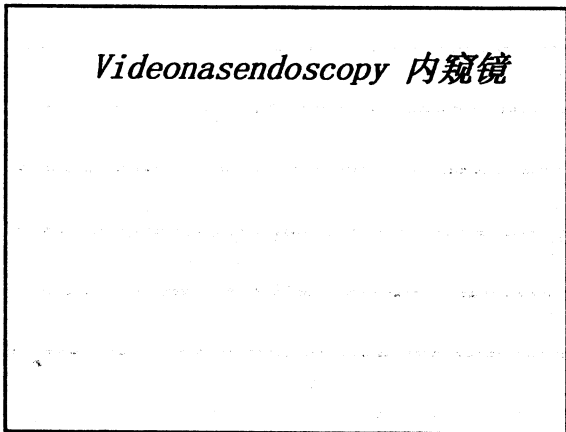
- Inserting through middle meatus 从中鼻道插入

- Good field of view, avoiding interference of velum 视野较好

FIGURE 8-5. Position of the fiberoptic in the pharynx. (Courtesy Machida, Inc.)

(Original figure from Courtesy Machida Inc.)

Videonasendoscopy 内窥镜



Videonasendoscopy 内窥镜

- Speech sample for nasendoscopy:

内窥镜检查的语音样本:

- Ask the patient to produce standard sentences

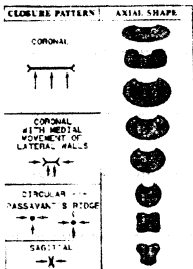
嘱患者说标准句 (无鼻辅音)

- "She wore blue shoes."
- "Coca-cola is good."

- Count 1 to 10

从一数到十

Videonasendoscopy 内窥镜

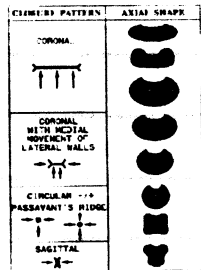


Patterns of velopharyngeal closure
腭咽闭合类型

- Coronal 冠状闭合
 - Mainly movement of velum
 - 主要是软腭向后运动

(Original figure from Finkelstein et al.)

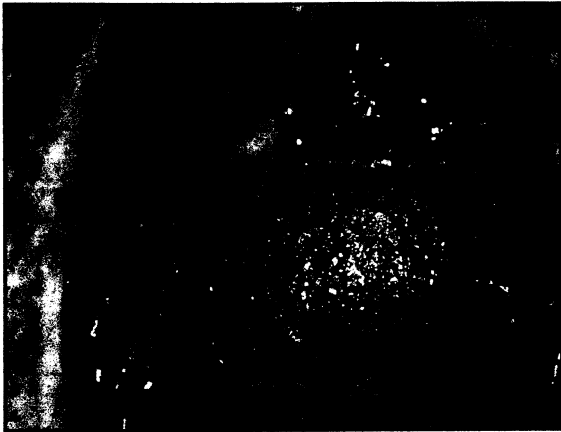Videonasendoscopy 内窥镜



Patterns of velopharyngeal closure
腭咽闭合类型

- Sagittal 矢状闭合
 - Mainly medial movement of lateral pharyngeal walls
 - 主要是咽侧壁向中线的运动

(Original figure from Finkelstein et al.)



Videonasendoscopy 内窥镜

• Advantages 优点:

- Direct observation of the velum and pharyngeal walls during speech, including movement of the lateral pharyngeal walls
直接观察说话时软腭和咽壁，包括咽侧壁的运动
- No exposure to radiation
无放射线危害

Videonasendoscopy 内窥镜

• Disadvantages 缺点:

- Invasiveness
侵入性操作
- Difficulty of application in young children
难以运用于幼龄儿童
- Subjective interpretation
主观判断

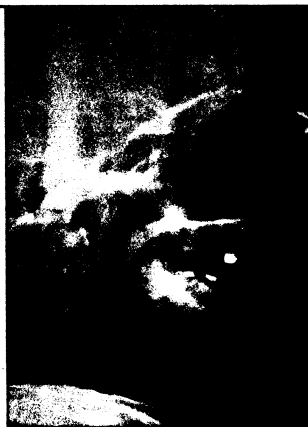X-ray assessment X线检查

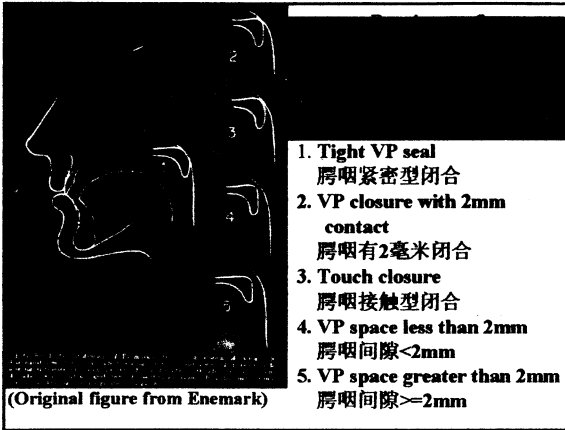
- Radiography (still image)
放射摄片
 - Lateral still radiography
侧位静态X线摄片
- Videofluoroscopy (motion image)
X线动态录像

Lateral Still Radiography
侧面静态X线摄片

- Taken at rest (velum at rest position)
休息位摄片 (软腭处于休息位)
- Taken during a sustained /s/
(velum lifted most significantly)
持续发/s/音时摄片 (软腭上提最显著)

**Lateral Still
Radiography**
侧面静态
X线摄片



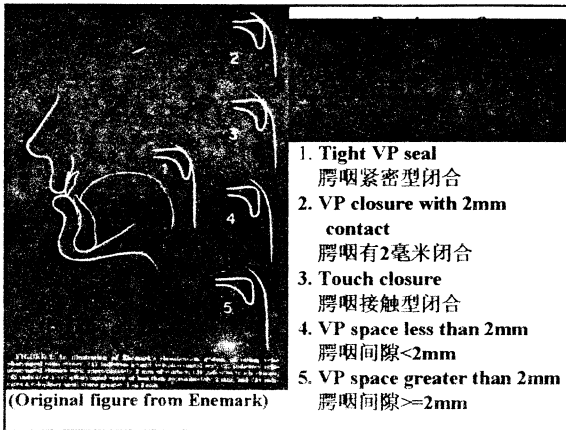


Lateral Still Radiography
 侧面静态X线摄片

- VPI and selecting treatment
 腭咽闭合功能不全与治疗的选择
- Measure the gap between the posterior pharyngeal wall and velum
 测量软腭到咽后壁的距离
- <2mm: behavior treatment
 <2mm: 行为治疗
- >=2mm: secondary cleft surgery
 >=2mm: 二期腭裂手术

Lateral Still Radiography
 侧面静态X线摄片

- Advantages 优点:
 - Direct observation of the VP mechanism
 直接观察腭咽闭合功能
 - Easy to obtain
 操作简便
 - Quantifiable
 测量可量化



Lateral Still Radiography
 侧面静态X线摄片

- VPI and selecting treatment
 腭咽闭合功能不全与治疗的选择

Measure the gap between the posterior pharyngeal wall and velum
 测量软腭到咽后壁的距离

- <2mm: behavior treatment
 <2mm: 行为治疗
- >=2mm: secondary cleft surgery
 >=2mm: 二期腭裂手术

Lateral Still Radiography
 侧面静态X线摄片

- Advantages 优点:
 - Direct observation of the VP mechanism
 直接观察腭咽闭合功能
 - Easy to obtain
 操作简便
 - Quantifiable
 测量可量化

Lateral Still Radiography
侧面静态X线摄片

- Disadvantage 缺点:
 - 2-D image 二维影像
 - Static image 静态影像
 - Exposure to radiation 放射性检查

Videofluoroscopy
X线动态录像

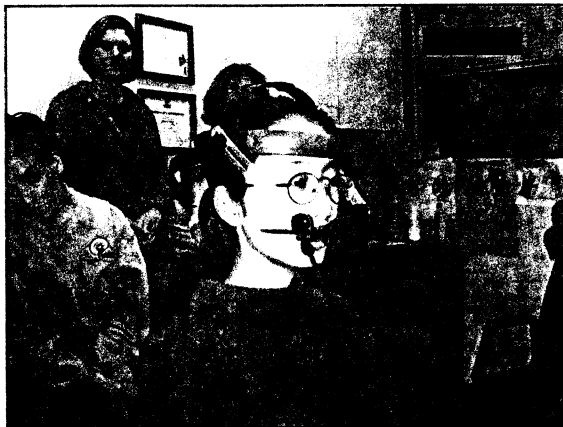- Fluoroscopic images are obtained with a camera and recorded on videotape.
- X线动态录像将功能活动的放射影像用录像的方式记录下来。

Videofluoroscopy
X线动态录像

- Advantages 优点:
 - Motion image during speech 说话时的动态影像
 - Can be applied in young children 可用于幼儿
- Disadvantages 缺点:
 - Exposure to radiation 放射性检查

Nasometer 鼻音计

- Nasometer is a microcomputer-based acoustic instrument designed for use in assessment and treatment of patients with nasality problems.
- 鼻音计是一种计算机化的声学仪器，主要用于评价和治疗鼻音异常的疾病。



Nasometer 鼻音计

- "Nasalance" = $[\text{nasal}/(\text{nasal} + \text{oral})] * 100$
鼻音率 = $[\text{鼻腔}/(\text{鼻腔}+\text{口腔})\text{声能}] * 100$

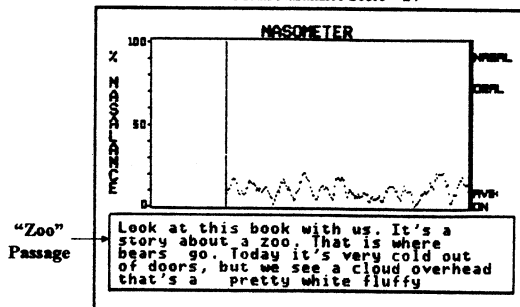
- Nasalance score significantly greater than "cut-off" score may imply hypernasality.
明显大于正常值高限提示过高鼻音。

Nasometer 鼻音计

- "cut-off" nasalance scores vary across centers.
正常值高限的标准随各个治疗中心而异。
- Dalston et al. (1991) 32%
- Hardin et al. (1992) 26%
- Watterson et al. (1996) 22%

Nasometer output

Mean Nasalance Score = 24



Nasometer 鼻音计

- Advantages 优点:
 - Instrumental assessment of oral/nasal acoustic resonance balance
口/鼻音共鸣平衡的客观评价
 - Non-invasiveness
非侵入性操作
- Disadvantages 缺点:
 - Indirect assessment
间接评价

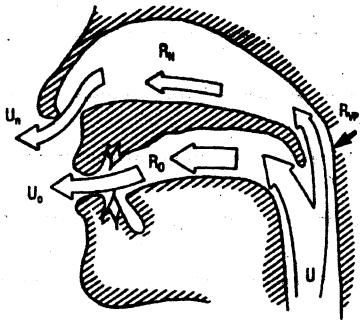
Aerodynamic Measures 空气动力学测量

- Also named as Pressure-Flow technique
又称压力-气流技术
- Speech is an aerodynamic event, measurement of the air flows and air pressure associated with both normal and disordered speech production can be expected to provide useful diagnostic information.
说话是一个空气动力学的运动过程，通过测量正常和异常说话时气流和气压的变化可以为诊断提供有意义的信息。

Aerodynamic Measures 空气动力学测量

- Estimation of the narrowest cross-sectional areas of the velopharyngeal port and of the nasal pathway.
估计腭咽部和鼻腔气道的最小横断面积。
- Determination of nasal coupling during speech.
测定说话时鼻腔与声道的联通。

Airflows (U) and resistance (R) in the upper vocal tract
 上部声道的气流和阻抗示意图



(Original figure from Baken)

FIGURE 10-8. Airflows (U) and resistances (R) in the upper vocal tract.

Aerodynamic Measures 空气动力学测量

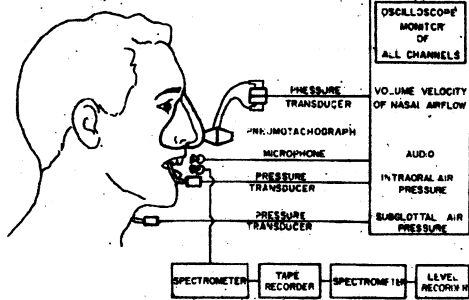
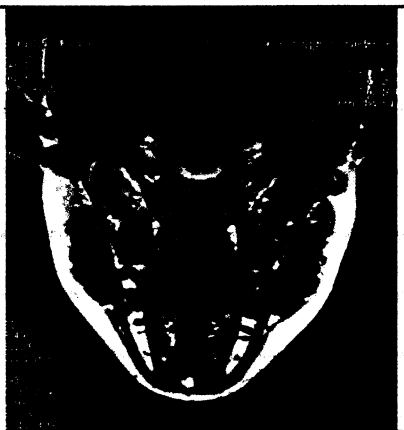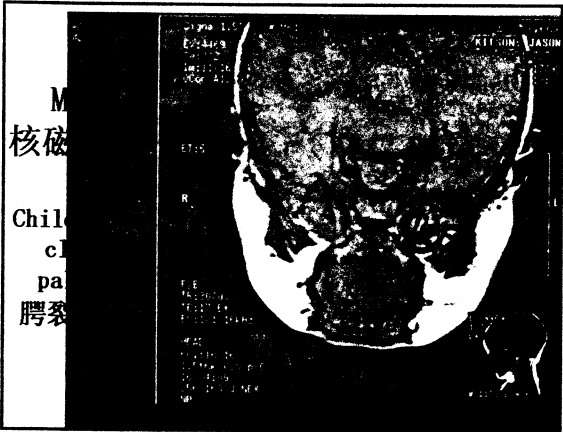


FIGURE 2. Block diagram of the instrumentation.

(Original figure from Bernthal and Beukelman)

MRI
 核磁共振
 Normal
 adult
 健康成人





**Clinical Evaluation of VP Function:
Instrumental Assessment
腭咽闭合功能的临床器械诊断**

• Summary 总结:

-First, perceptually determine whether a speech problem exists that might be related to VPI.
首先进行主观感觉的评价，以确定是否存在与腭咽闭合不全相关的语音问题。

**Clinical Evaluation of VP Function:
Instrumental Assessment
腭咽闭合功能的临床器械诊断**

• Summary 总结:

-If there is, then perform an instrumental assessment to determine the specific nature and degree of VP impairment.
如果存在，继而进行器械检查以确定腭咽闭合不全的性质和程度。

**Clinical Evaluation of VP Function:
Instrumental Assessment
腭咽闭合功能的临床器械诊断**

• **Summary 总结:**

-Results of the instrumental assessment then can be used to guide the type of treatment recommended.

器械检查的结果可作为选择治疗方法的参考。
